

Corakjn

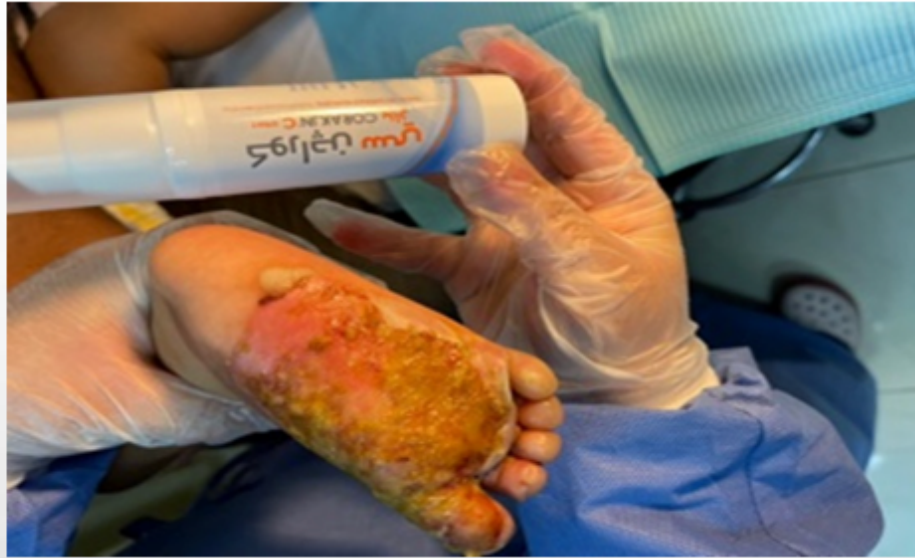

REPAIR
REGENERATION

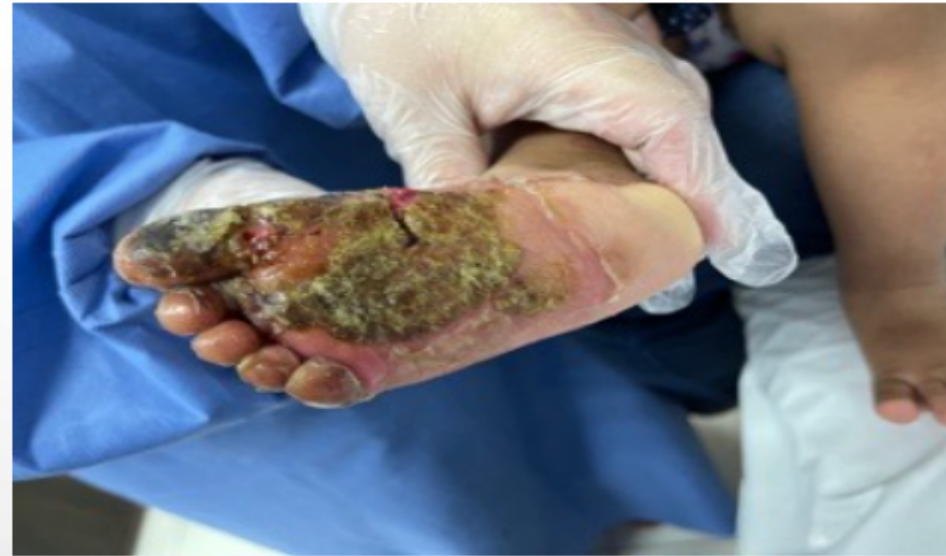REGE
NERA
TION
3.0

CORAKJN®
From Repair to Regeneration

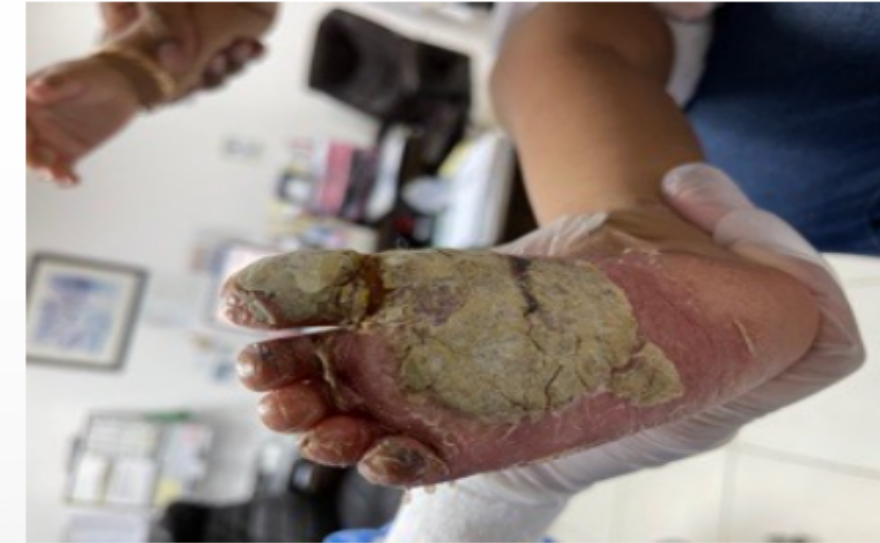Corakjn has a superior results in Burns even II and III grade



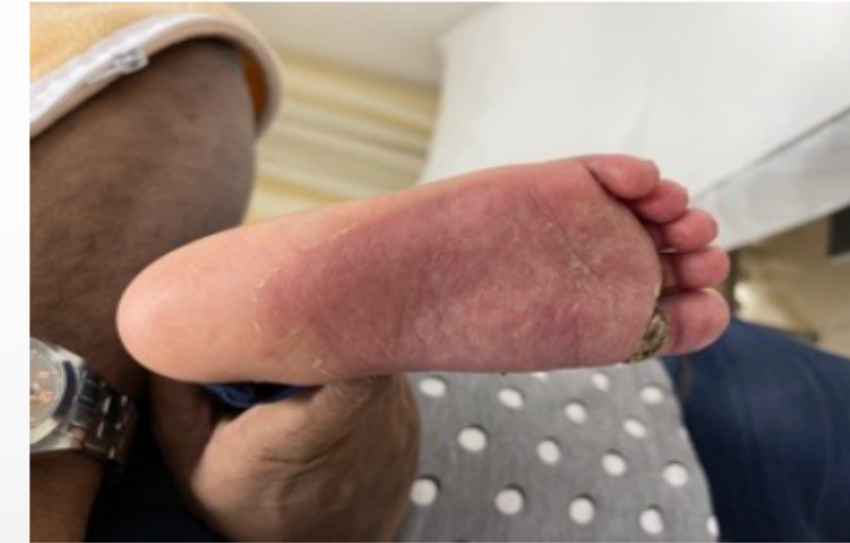24 May 2021



26 May 2021

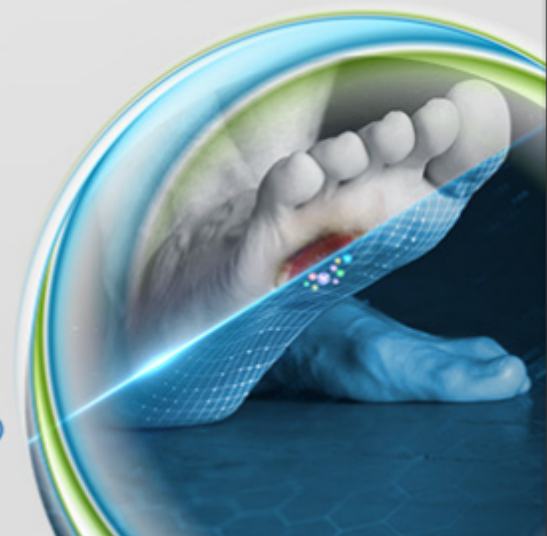


2 June 2021

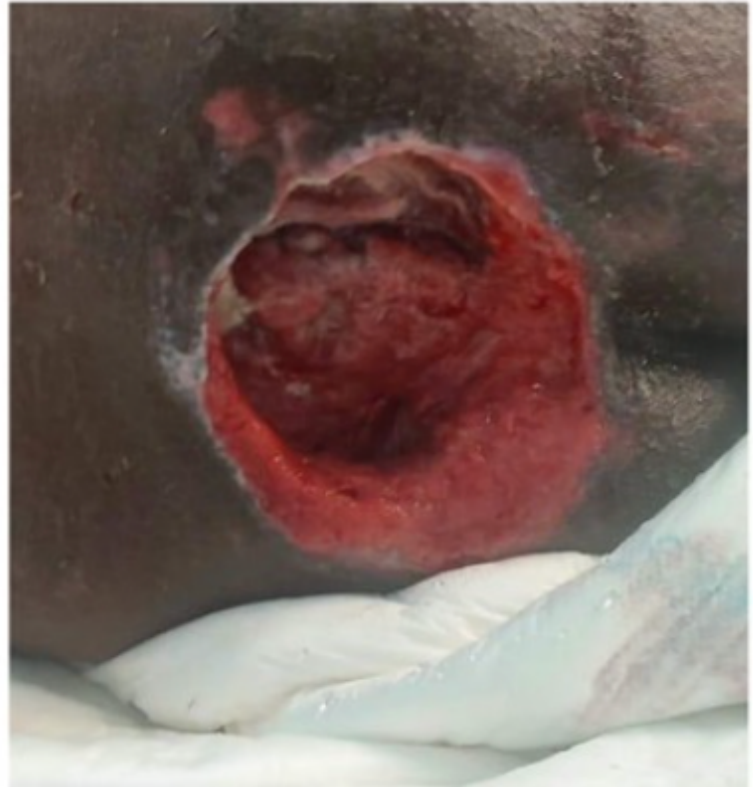


10 June 2021

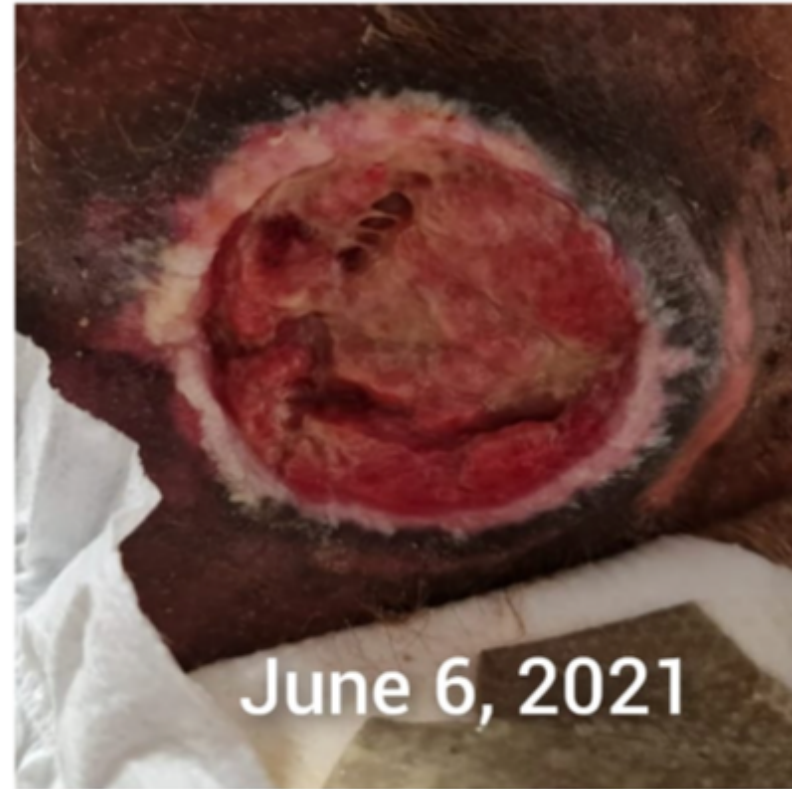CORAKJN®



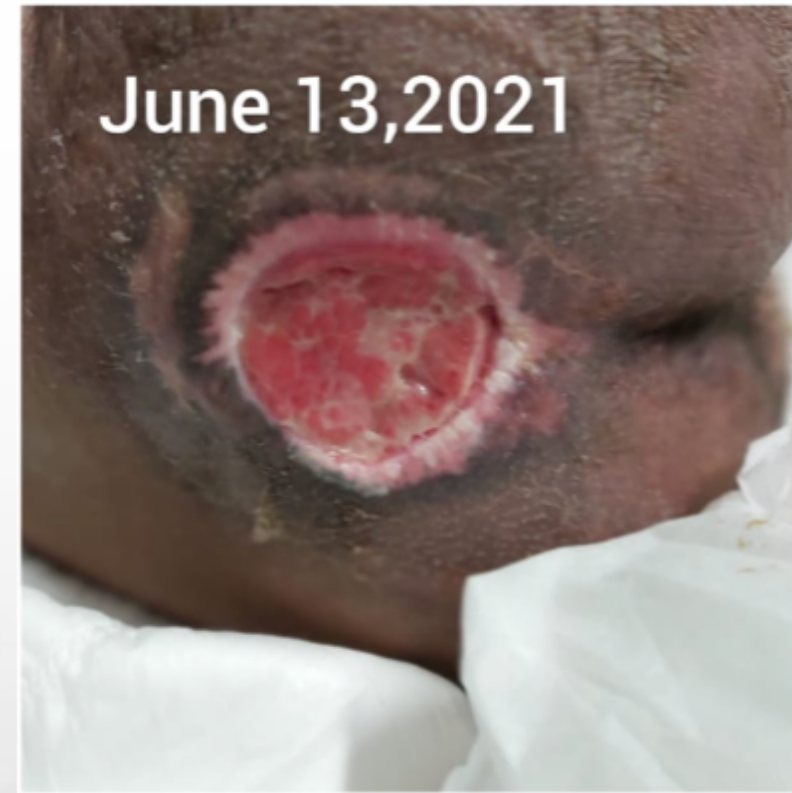Corakjn has excellent results in very complicated cases of bed sores grade IV which not responded to current advanced medications



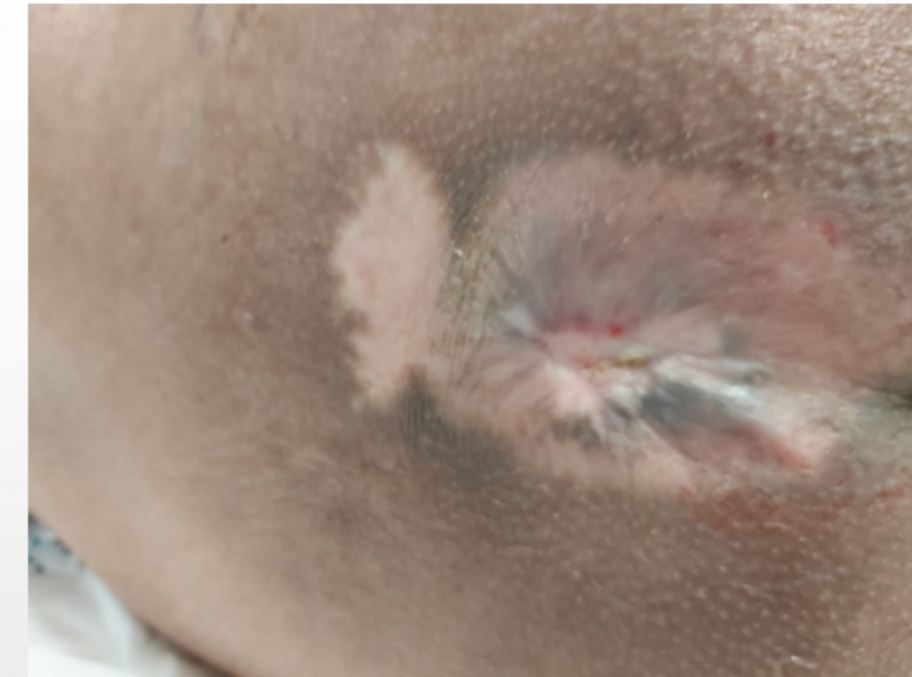
13/4/2021 before
VAC therapy
Wound size 8x11x3
Cm



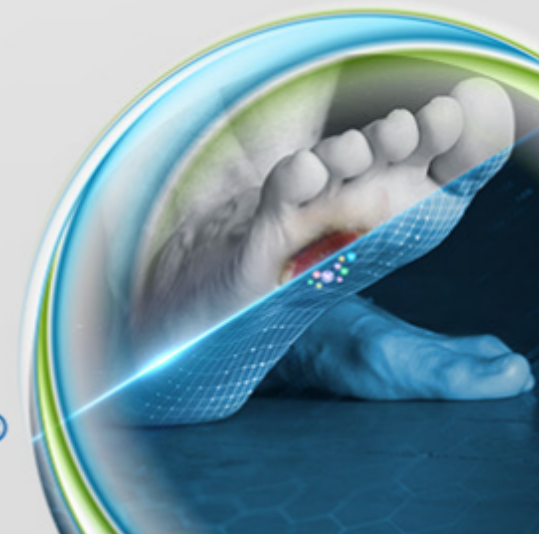
Corakjn Start
Spray and gel



Wound Size : 6cmx6cm
leveled with the skin
and significant increase
in granulation tissues



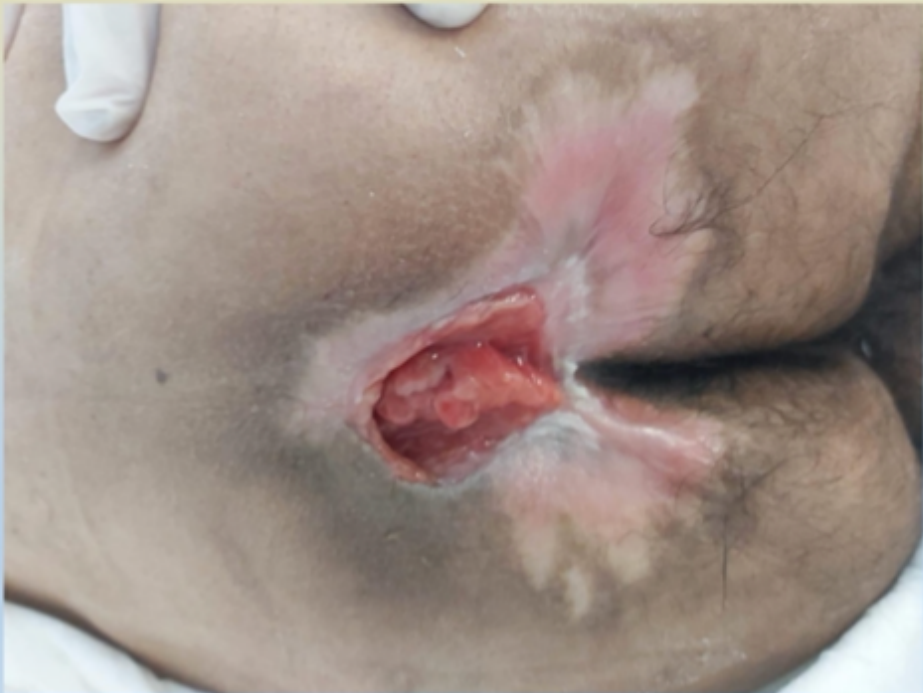CORAKJN®



Pressure ulcer IV

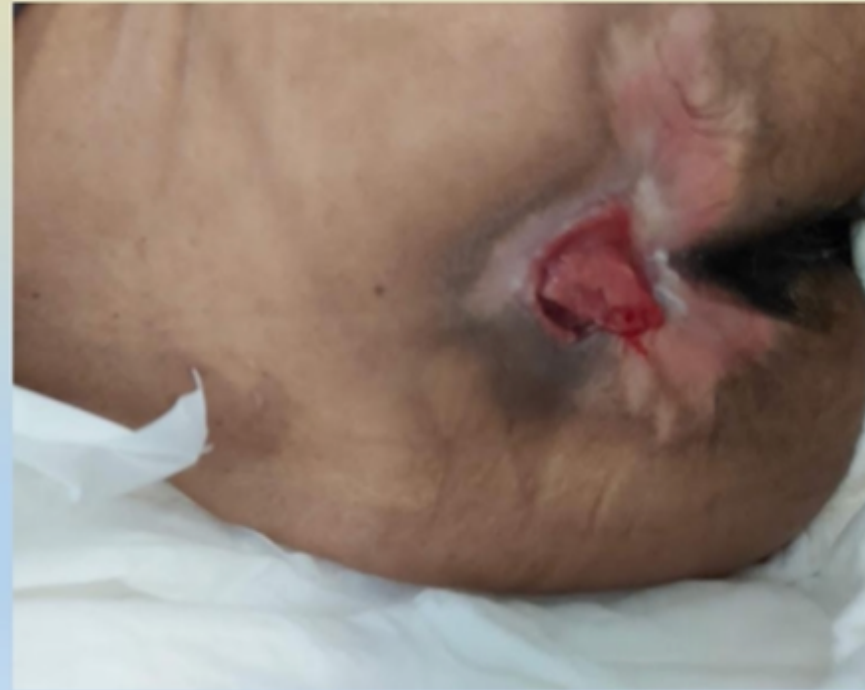6-June-2021

Started treatment with Corakjn Spray and Cream
Wound Size: 4cm x 4cm with granulation tissues noted



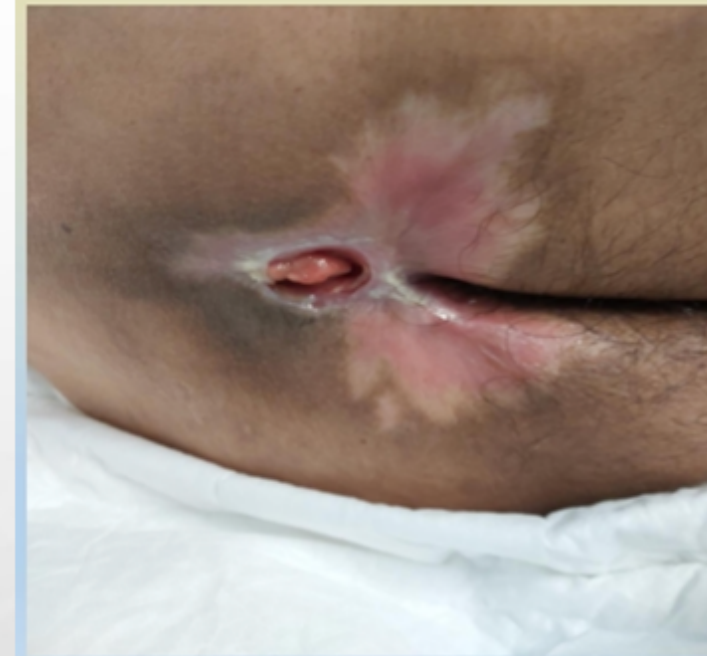14-June-2021

Wound Size: 3cm x 2cm
Hyper-granulation tissues developed



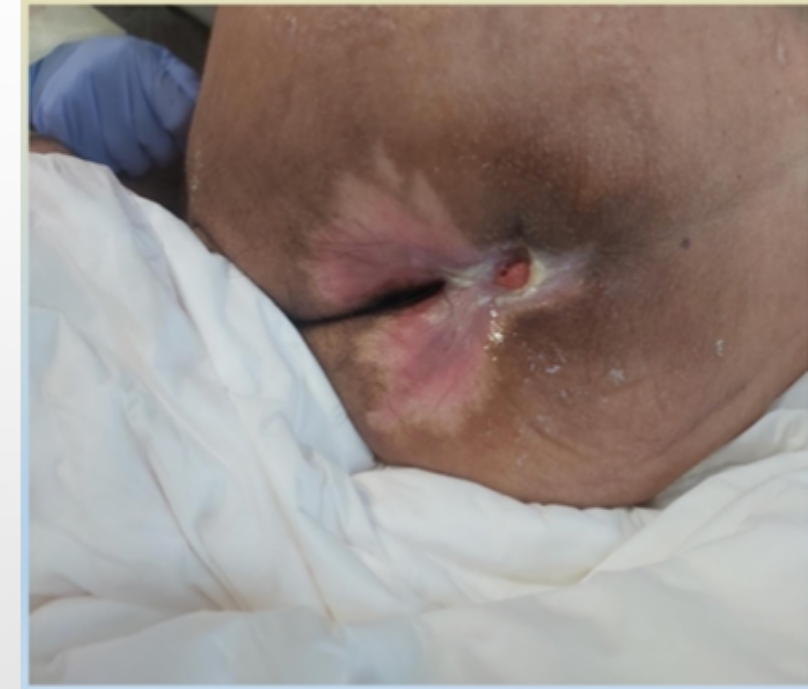12-July-2021

Wound Size: 1.5cm x 1cm
Hyper-granulation was treated with silver nitrate
Along with continuous Corakjn Spray and Silver



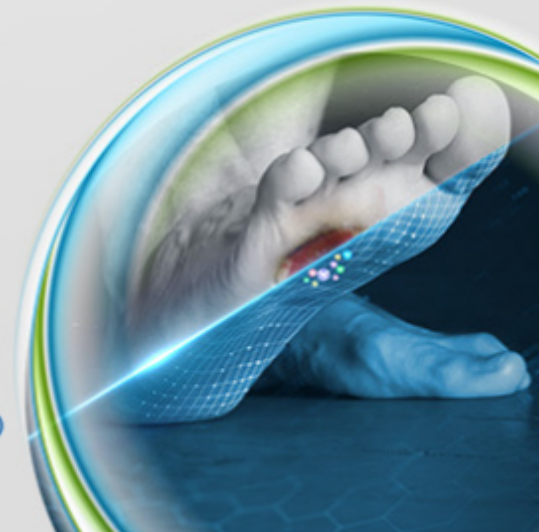
28-July-2021

Wound Size: 0.5cm x 0.5cm
Hyper-granulation tissues gone.

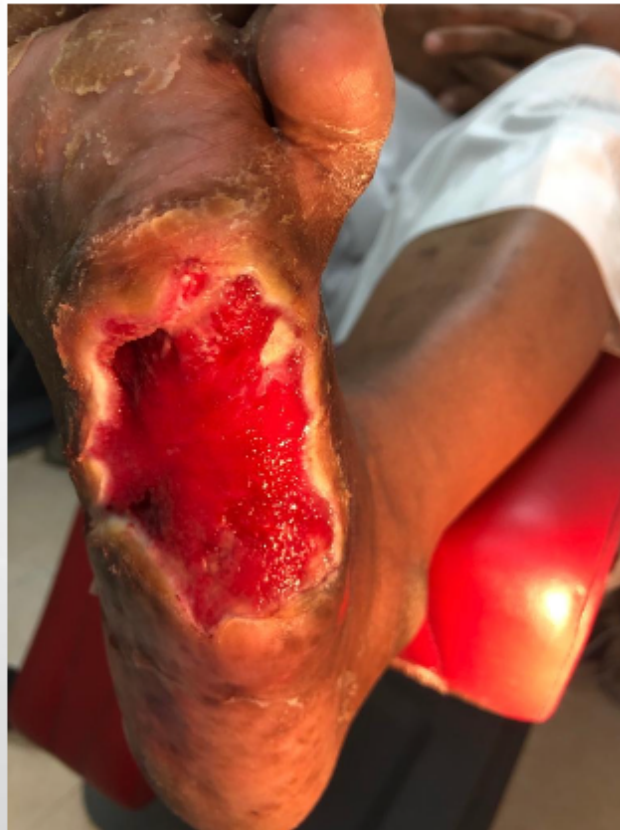

Sacral Pressure Injury Stage 4 Wound size: 4x4cm 49 years old male, with DM, dyslipidemia, psychiatric illness, community acquire pneumonia admitted for management and long term care.

CORAKJN®



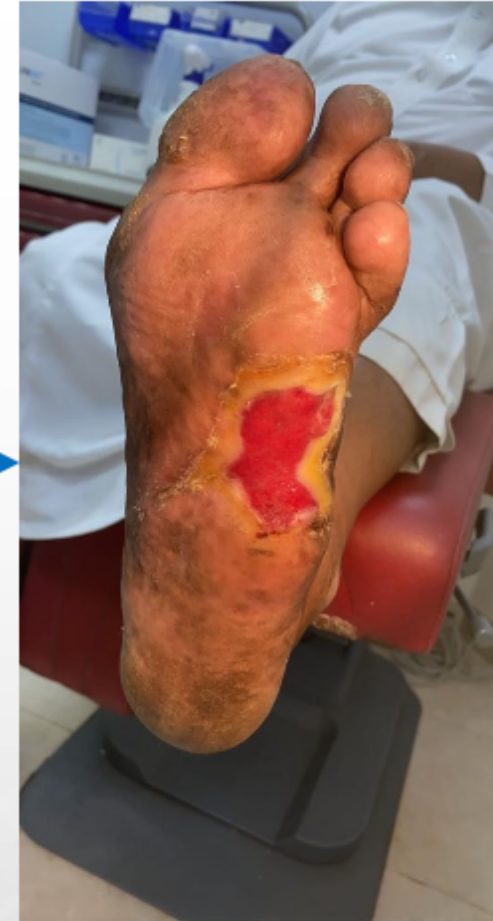Corakjn has significant result



16/6/2021

Diabetic patient 63 years
old with DFU - Tabuk Area

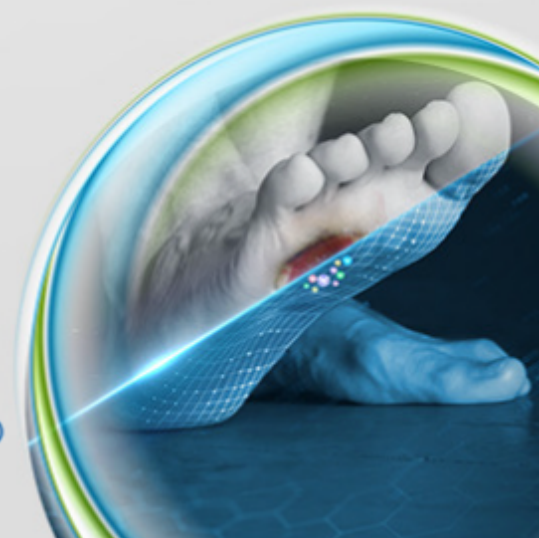
Two Months
results



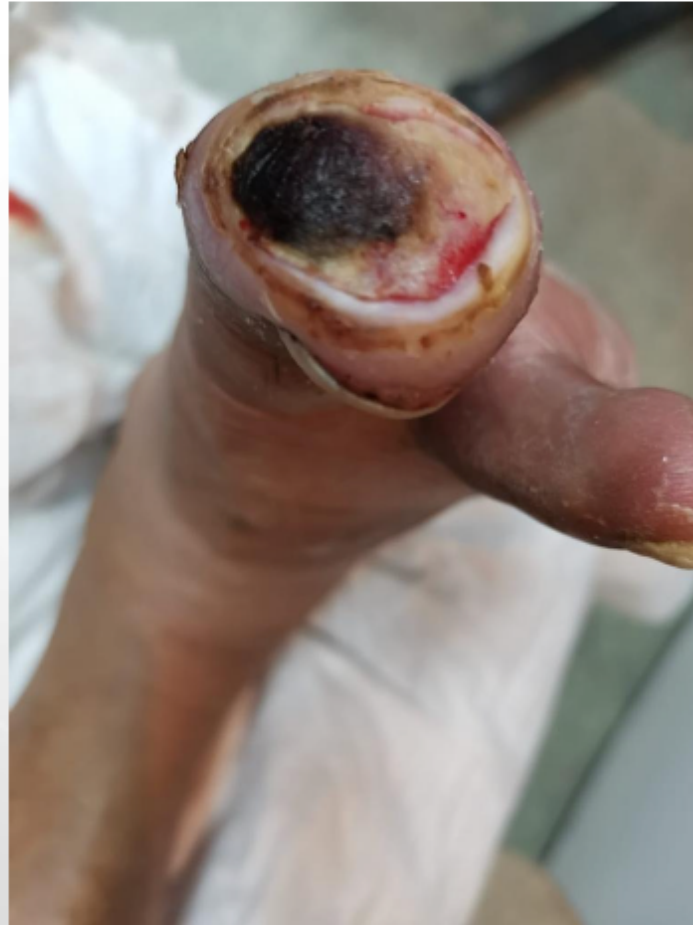14/7/2021

Doctor feedback
1- Corakjn fast the healing
2- Better quality of scar

CORAKJN®

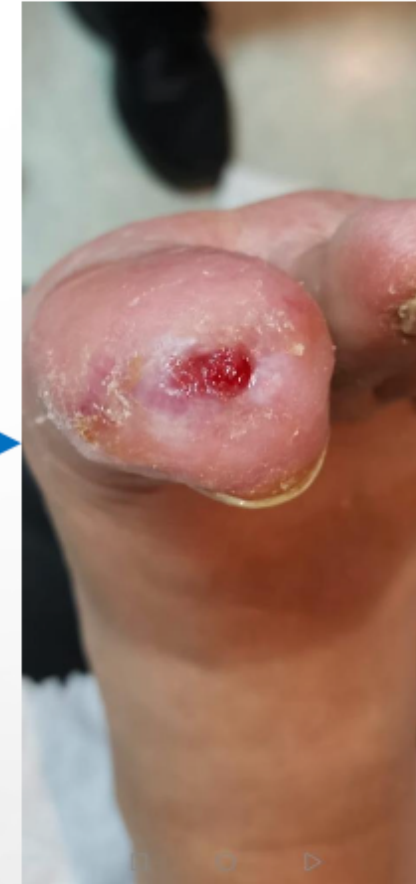

Diabetic foot ulcer



17/6/2021

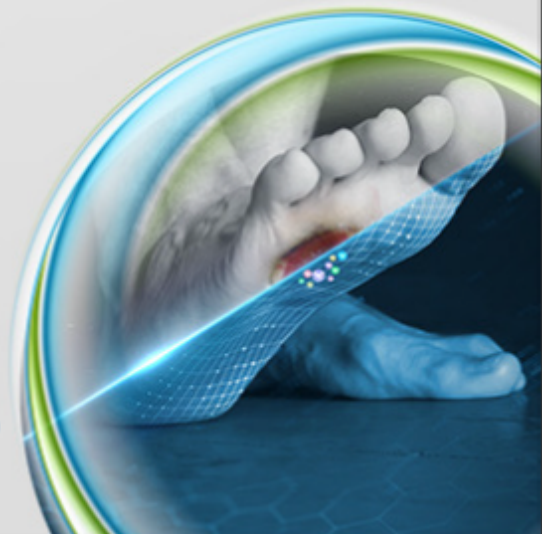
After 20 days only
of using corakjn
spray and Cream



6/7/2021

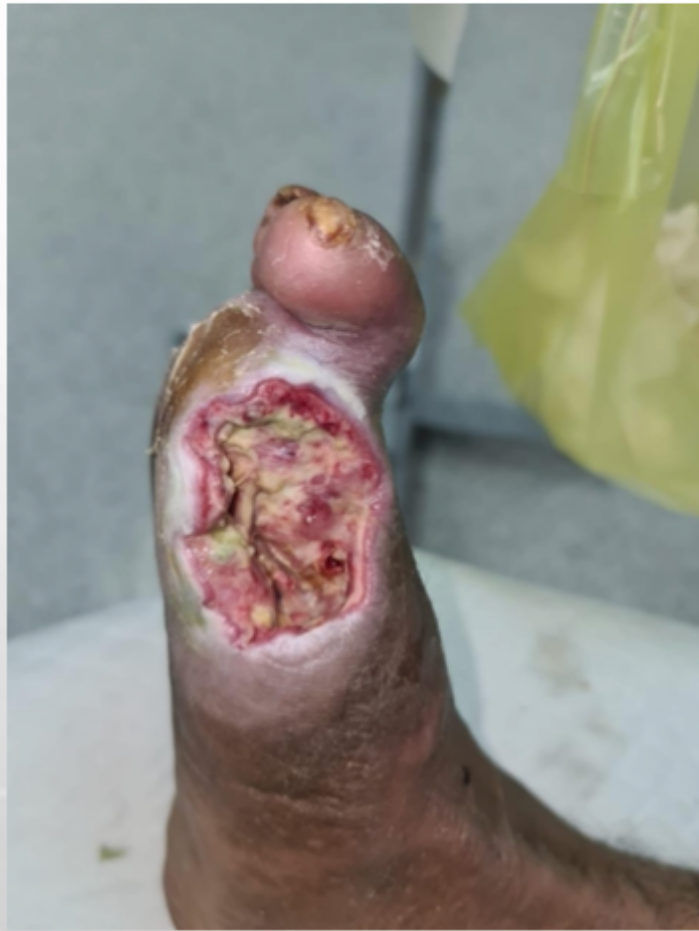Dammam: Case1, Diabetic
foot ulcer With necrotic
tissues: 61 years old male

CORAKJN®

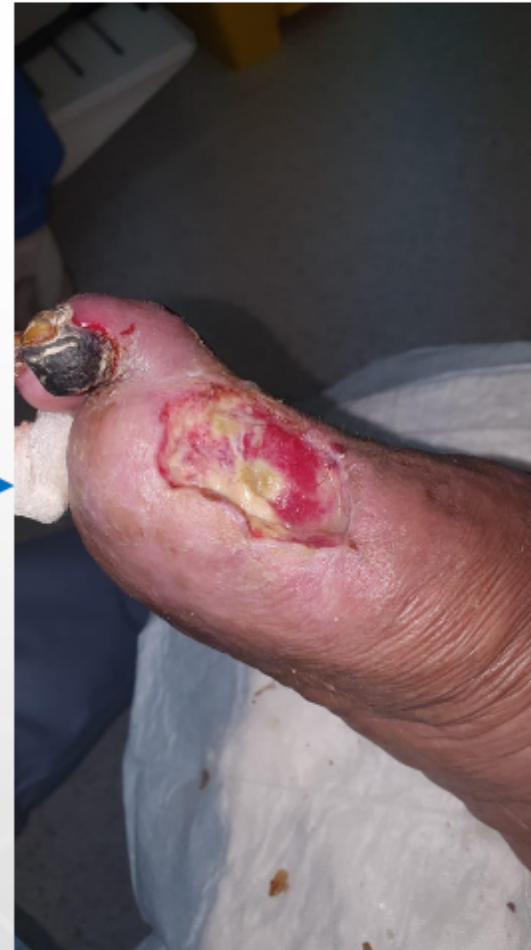

Jeddah Case

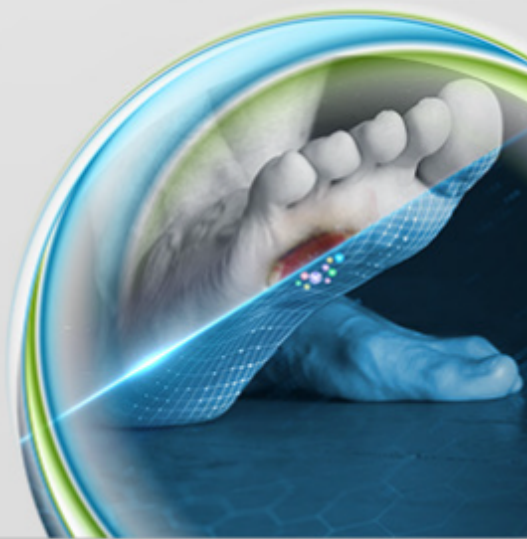
Using twice weekly



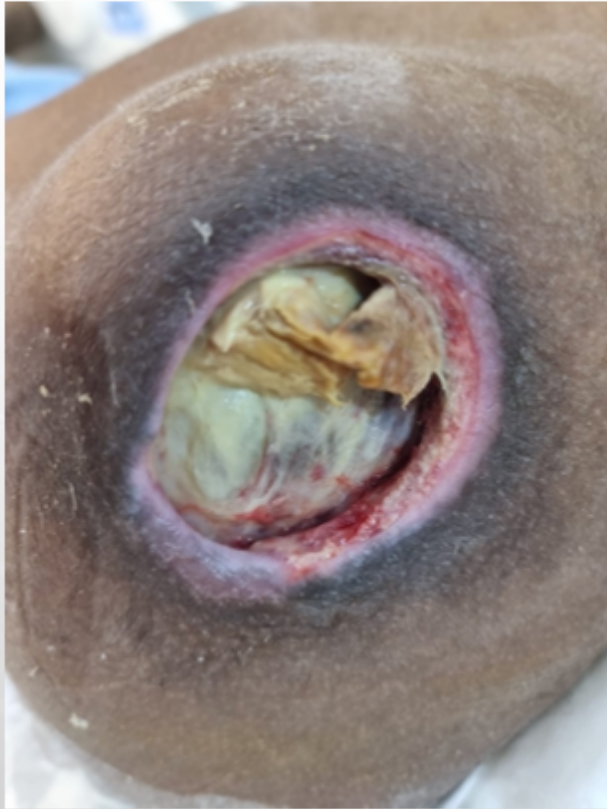After one week of
irregular use of
Corakjn (twice
weekly)



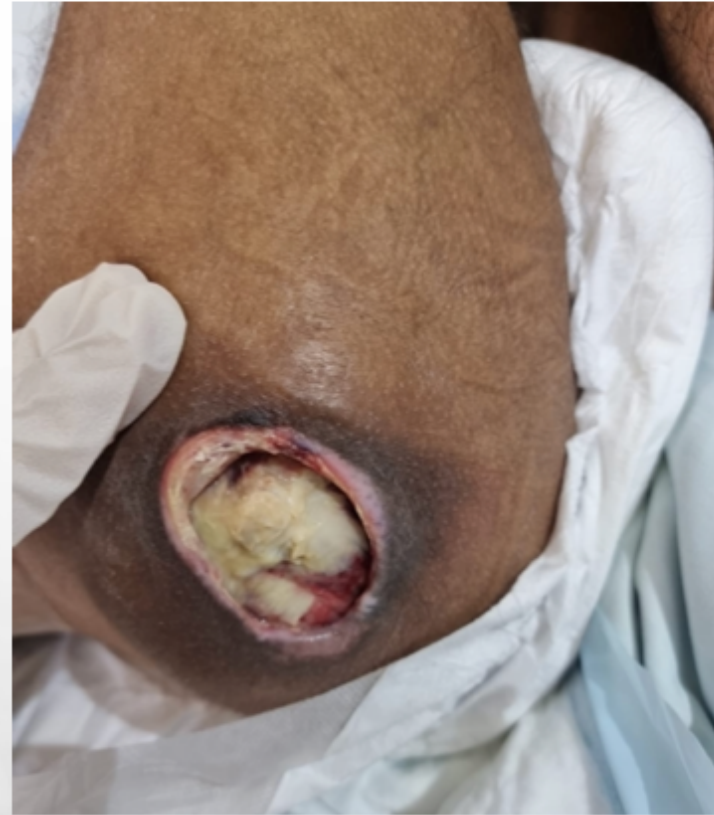CORAKJN®



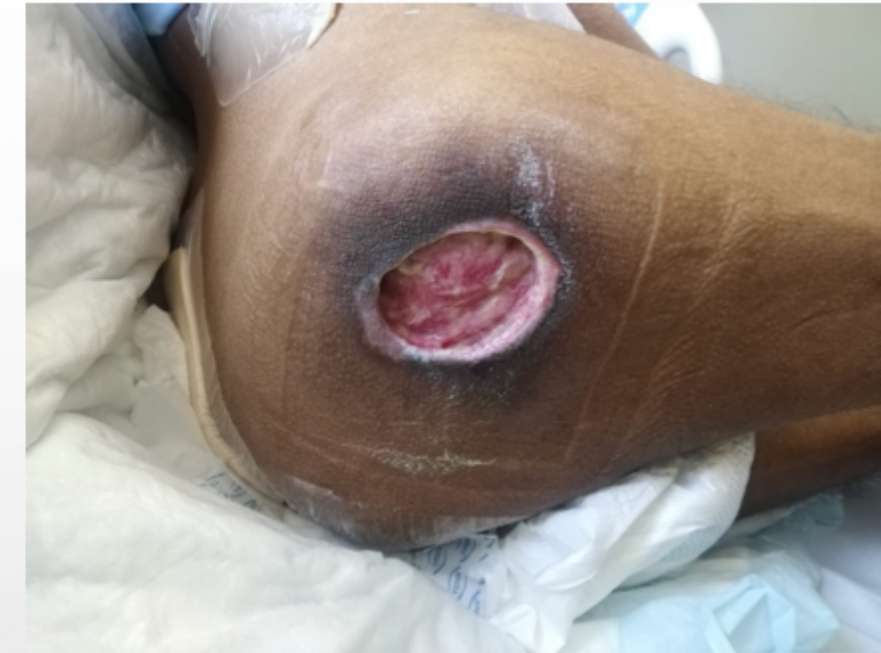Fast results in one of the governmental hospitals



Start treatment
on Corakjn on
28th Oct 2021

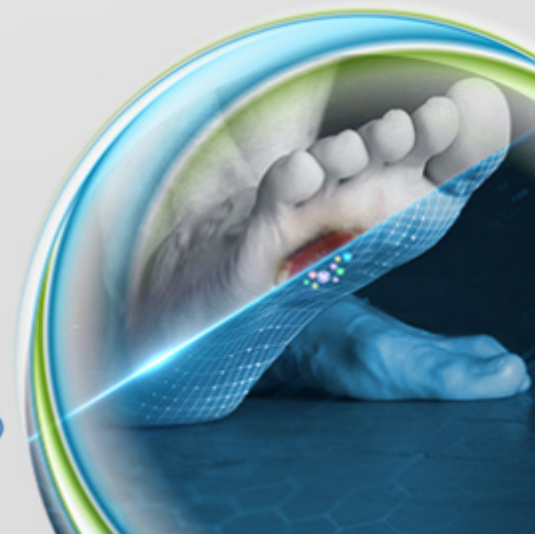


Result on 8th
Nov.



Result on 16th
Nov.

CORAKJN®



THANK YOU